



Contents lists available at ScienceDirect

Pediatric Neurology

journal homepage: www.elsevier.com/locate/pnu

Review Article

Pyridoxine-Dependent Epilepsy: An Expanding Clinical Spectrum

Clara D.M. van Karnebeek MD, PhD^{a,b,c,*}, Sylvia A. Tiebout MD^a,
 Jikkemien Niermeijer MD^d, Bwee Tien Poll-The MD, PhD^e, Aisha Ghani BA^{a,c},
 Curtis R. Coughlin II MS, MBE^f, Johan L.K. Van Hove MD, PhD^f,
 Jost Wigand Richter MD^{g,h}, Hans Juergen Christen MD, PhD^{g,h},
 Renata Gallagher MD, PhDⁱ, Hans Hartmann MD^j,
 Sylvia Stockler-Ipsiroglu MD, PhD^{a,c,**}

^a Division of Biochemical Diseases, Department of Pediatrics, BC Children's Hospital, University of British Columbia, Vancouver, British Columbia, Canada

^b Centre for Molecular Medicine and Therapeutics, University of British Columbia, Vancouver, British Columbia, Canada

^c Treatable Intellectual Disability Endeavor in British Columbia (TIDE-BC), Vancouver, British Columbia, Canada

^d Department of Neurology, St Elisabeth Twee Steden Hospital, Tilburg, The Netherlands

^e Department of Pediatric Neurology, Emma Children's Hospital, University of Amsterdam, AMC, Amsterdam, The Netherlands

^f Section of Clinical Genetics and Metabolism, Department of Pediatrics, University of Colorado, Aurora, Colorado, USA

^g Department of Pediatrics, Children's Hospital auf der Bult, Hannover, Germany

^h Department of Neuropediatrics, Children's Hospital auf der Bult, Hannover, Germany

ⁱ Department of Medical Genetics, University of California San Francisco, San Francisco, California, USA

^j Department of Pediatric Kidney, Liver and Metabolic Diseases, Hannover Medical School, Hannover, Germany

ABSTRACT

BACKGROUND: Pyridoxine-dependent epilepsy is a rare autosomal recessive epileptic encephalopathy caused by antiquitin (*ALDH7A1*) deficiency. In spite of adequate seizure control, 75% of patients suffer intellectual developmental disability. Antiquitin deficiency affects lysine catabolism resulting in accumulation of α -aminoadipic semialdehyde/pyrroline 6' carboxylate and pipercolic acid. Beside neonatal refractory epileptic encephalopathy, numerous neurological manifestations and metabolic/biochemical findings have been reported. **METHODS AND RESULTS:** We present a phenotypic spectrum of antiquitin deficiency based on a literature review (2006 to 2015) of reports ($n = 49$) describing the clinical presentation of confirmed patients ($n > 200$) and a further six case vignettes. Possible presentations include perinatal asphyxia; neonatal withdrawal syndrome; sepsis; enterocolitis; hypoglycemia; neuroimaging abnormalities (corpus callosum and cerebellar abnormalities, hemorrhage, white matter lesions); biochemical abnormalities (lactic acidosis, electrolyte disturbances, neurotransmitter abnormalities); and seizure response to pyridoxine, pyridoxal-phosphate, and folinic acid dietary interventions. **DISCUSSION:** The phenotypic spectrum of pyridoxine-dependent epilepsy is wide, including a myriad of neurological and systemic symptoms. Its hallmark feature is refractory seizures during the first year of life. Given its amenability to treatment with lysine-lowering strategies in addition to pyridoxine supplementation for optimal seizure control and developmental outcomes, early diagnosis of pyridoxine-dependent epilepsy is essential. All infants presenting with unexplained seizures should be screened for antiquitin deficiency by determination of α -aminoadipic semialdehyde/pyrroline 6' carboxylate (in urine, plasma or cerebrospinal fluid) and *ALDH7A1* molecular analysis.

Keywords: metabolic epilepsy, neonatal encephalopathy, seizures, B6 vitamers, lysine catabolism, treatment

Pediatr Neurol 2016; ■: 1-7

© 2016 Elsevier Inc. All rights reserved.

Disclosure Conflicts of Interest: The authors have no conflict of interest to disclose.

Article History:

Received August 4, 2015; Accepted in final form December 18, 2015

* Communications should be addressed to: Dr. van Karnebeek; Division of Biochemical Diseases (Room K3-201); BC Children's Hospital Department of Pediatrics and Centre for Molecular Medicine and

Therapeutic; University of British Columbia; 4480 Oak Street; Vancouver, British Columbia V6H 3V4, Canada.

** Dr. Stockler-Ipsiroglu; Division of Biochemical Diseases (Room K3-205); BC Children's Hospital Department of Pediatrics; University of British Columbia; 4480 Oak Street; Vancouver, British Columbia V6H 3V4, Canada.

E-mail addresses: cvankarnebeek@cw.bc.ca; sstockler@cw.bc.ca

Introduction

Pyridoxine-dependent epilepsy is a rare autosomal recessive disorder, classically presenting with neonatal seizures that can be controlled with pharmacologic doses of pyridoxine.^{1,2} Since the 1950s, pyridoxine-dependent epilepsy was diagnosed clinically with vitamin B6 as a diagnostic trial.³ The reported incidence varies from 1:20,000⁴ to 1:276,000⁵ and 1:783,000.³ In 2006 a defect in the lysine degradation pathway (*ALDH7A1* encoding α -amino adipic semialdehyde dehydrogenase, also known as anti-quitin [ATQ]) was identified as the genetic basis of this rare epilepsy.⁶ Accumulation of α -amino adipic semialdehyde (α -AASA)/L- Δ 1-piperidine-6 carboxylate (P6C) results in chemical inactivation of pyridoxal phosphate (PLP).⁶ These insights unveiled novel diagnostic biomarkers and the lysine degradation pathway as adjunct treatment targets⁷⁻¹⁰ (Fig 1). To compile an overview of possible clinical presentations,¹¹ we performed a literature review to collect data on reported pyridoxine-dependent epilepsy patients. Case vignettes are presented to illustrate the clinical spectrum.

Materials and Methods

This study was approved by the Ethics Boards at British Columbia Children's and Women's Hospital, University of British Columbia (Canada) and the University of Colorado (United States of America). Parents provided informed consent for publication of the case vignettes.

For the literature review, we searched PubMed (<http://www.ncbi.nlm.nih.gov/pubmed>; 2006 to October 2015) using a combination of the following terms (restricted to humans): pyridoxine-dependent epilepsy (PDE), pyridoxine-dependent seizures, Antiquitin, ATQ, α -amino adipic semialdehyde dehydrogenase, *ALDH7A1*, α -amino adipic semialdehyde, and α -AASA. For the selection of articles, we applied the following criteria: (1) publication date after the discovery of *ALDH7A1* mutations as the cause of pyridoxine-dependent epilepsy in 2006⁶; (2)

publication language English; and (3) reporting one or more pyridoxine-dependent epilepsy patient(s) with confirmed ATQ deficiency, including a description of the clinical symptoms.

We subsequently extracted clinical, biochemical, and neuroimaging data/symptoms from the selected articles. For each of the reported symptoms, the following classification was made (Fig 2): either "classical," defined as the typical or core phenotypic presentation (reported in the vast majority of patients) or "spectrum," defined as less common or atypical (reported in minority of patients). The "spectrum symptoms" were organized into different categories: neurologic, biochemical, neuroimaging findings; seizure onset; seizure type; and response to medication other than pyridoxine, behavioral/psychiatric, and "other" symptoms. We indicated the ultrarare symptoms, i.e., those reported in less than five patients in the literature. To overcome the limitations of our PubMed search and subsequent potential "reporting bias" (i.e., that only a selection of pyridoxine-dependent epilepsy patients is published as a case report), we also asked clinicians (all nine coauthors) with expertise and experience in ATQ deficiency to review and edit the clinical spectrum generated by the literature review, i.e., whether any symptoms were missing or unjustified and provide illustrative case vignettes.

Results

Of the 246 articles generated by the PubMed search, 49 met the outlined criteria, including 266 descriptions of patients with confirmed ATQ deficiency.^{5,7,8,11-55} Figure 2 provides a comprehensive visual overview of the presenting clinical and biochemical features of patients reported in the literature.

Patient vignettes

One or more of the authors follow each of the patients described below. Although Patients 2 and 4 are novel, i.e., have not previously been reported in the literature, we have expanded on the remaining published reports to include more recent information.

Patient #1: lactic acidosis and cardiomyopathy mimicking mitochondrial disease

This girl was born at 33 weeks, then developed recurrent apnea; distended abdomen; feeding intolerance; lactic acidosis; hyponatremia; and increased urinary excretion of lactate, ketone bodies, and dicarboxylic acids on day one.¹² On day ten, choreoathetoid movements of arms and legs, orofacial twitches, and burst suppression pattern on electroencephalograph (EEG) were unresponsive to phenobarbital but improved after the administration of 100 mg of pyridoxine intravenously. A magnetic resonance imaging (MRI) revealed bilateral temporal lobe hemorrhages and thalamic changes. ATQ deficiency was confirmed by homozygosity for a known pathogenic sequence change (c.1279G>C; p.E427Q) in *ALDH7A1*. During the first year of life, she remained seizure free on oral pyridoxine (15 to 30 mg/kg/day). At age 11 months, a lysine-restricted diet was initiated with addition of arginine at age 6.3 years. This regimen has been well tolerated, with pipercolic acid normalizing and α -AASA dropping below the detection limit; at age seven years of age, aside from mild motor delay, she demonstrates normal psychomotor development.^{7,8}

Patient #2: recurrent burst suppression on oral pyridoxine and periventricular leukomalacia

This girl was born spontaneously at 34 weeks gestation, then exhibited generalized myoclonus, particularly

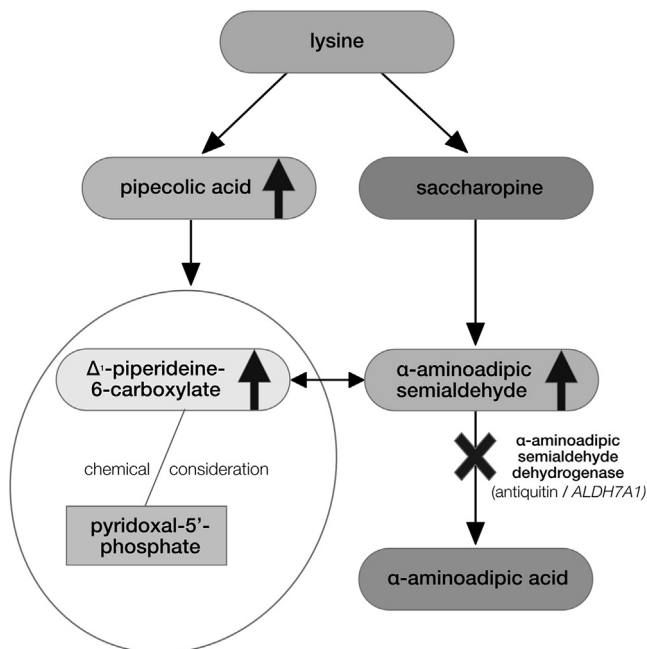


FIGURE 1. Role of anti-quitin (*ALDH7A1*) in the catabolic pathway of lysine.

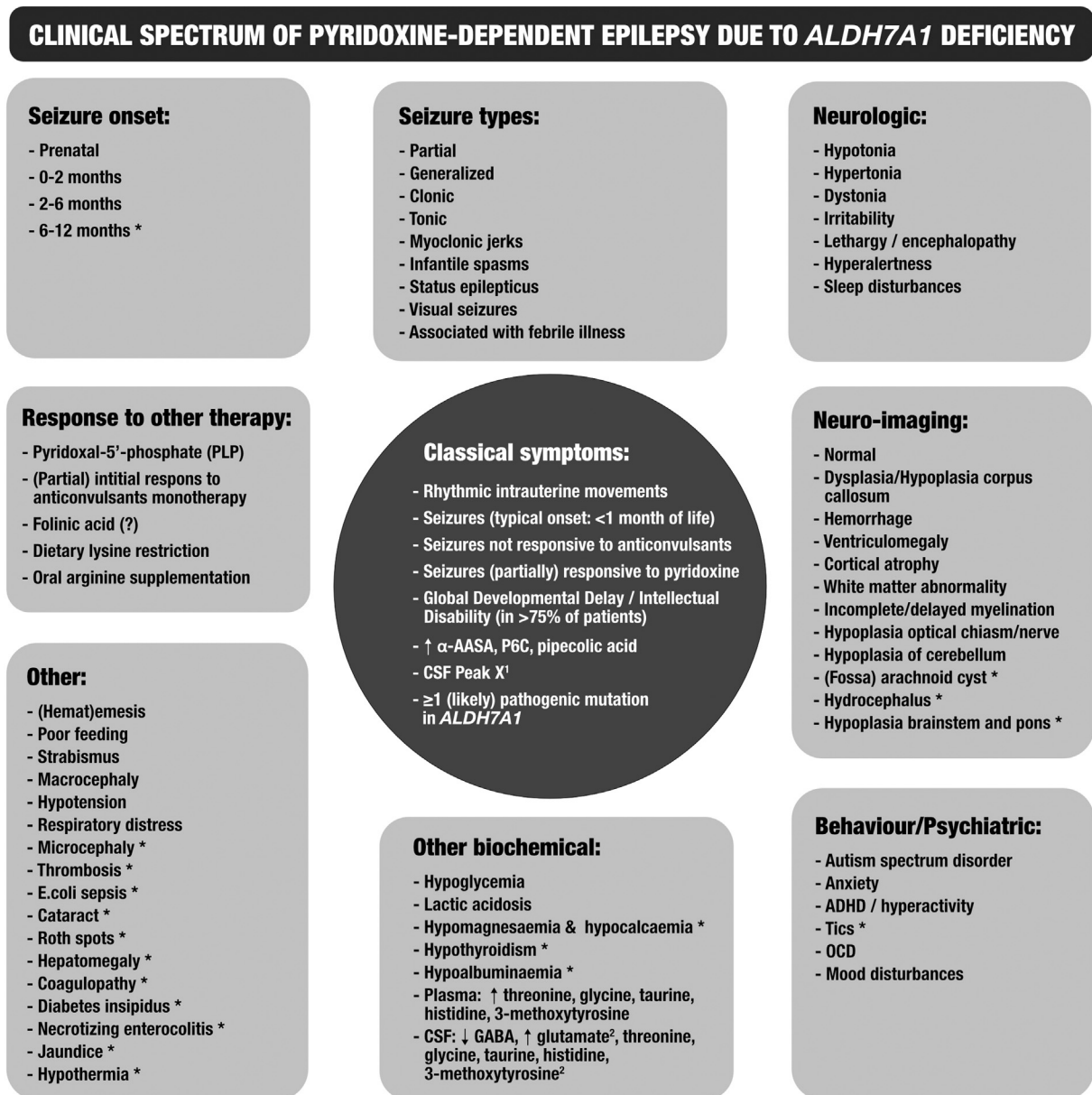


FIGURE 2.

Overview of the symptoms reported in the literature for patients with ATQ deficiency. Classical symptoms (center circle): clinical and biochemical symptoms observed in the vast majority patients. Spectrum symptoms (boxes): symptoms present in the minority of patients. *Ultrarare symptoms, reported in less than five literature cases. ¹Unidentified peak in the HPLC chromatogram for CSF monoamine neurotransmitter analysis in ATQ deficiency patients. ²Potentially normalize on pyridoxine therapy. α -AASA, α -amino adipic semialdehyde; ADHD, attention deficit hyperactivity disorder; ATQ, anti-quitin; CSF, cerebrospinal fluid; HPLC, high performance liquid chromatography; GABA, *gamma*-aminobutyric acid; OCD, obsessive–compulsive disorder; P6C, L- Δ 1-piperidine-6 carboxylate.

of the diaphragm, lactic acidosis (9.8 mmol/L, reference range < 2.1), and an EEG illustrating a high-voltage burst suppression pattern on day one. Therapy with IV phenobarbital and lidocaine was ineffective, whereas one dosage of intravenous pyridoxine 100 mg resulted in immediate cessation of myoclonus on day two. An MRI brain scan on day eight indicated a small subependymal hemorrhage in the right hemisphere and diffuse punctate bleeding in the periventricular white matter. ATQ deficiency was confirmed by increased pipercolic acid in cerebrospinal fluid (CSF; 11.6 μ mol/L, reference range = 0.00

to 0.10) and in plasma (32.7 μ mol/L, reference range = 0.1 to 7.0), and homozygous mutations (c.1286G>T; p.S429L) in *ALDH7A1*.

While on pyridoxine (30 mg/kg/day) and folinic acid (3 to 5 mg/kg/day), breakthrough seizures occurred during febrile episodes at nine and 21 months of age. An MRI at age 14 months indicated widened extracellular spaces and periventricular leukomalacia with diffuse white matter loss, a more severe than the usual evolution observed in ex-premature patients. At age three years, she has mild delay in gross and fine motor skills.

Patient #3: myoclonia with onset beyond the neonatal period and folinic acid-responsive seizures

This boy with an unremarkable perinatal history had episodes of eye deviation, jerking movements of arms and legs accompanied by irritability, and crying at age 2.5 months. In retrospect, episodic jerking of the eyes and legs had been noticed since birth. The results of EEG, performed for the first time after an initial phenytoin and phenobarbital load, was normal, whereas abnormal movements disappeared only after a dose of oral pyridoxine (100 mg twice daily). At 4.5 months, he was diagnosed with “folinic acid-responsive seizures,” based on the presence of “peak X” in his CSF.¹³ At age 12 months, breakthrough seizures occurred after he missed several dosages of pyridoxine. ATQ deficiency was diagnosed based on elevated plasma pipercolic acid (7.9 $\mu\text{mol/L}$, normal < 3), elevated urinary α -AASA (32.7 $\mu\text{mol/L}$; reference range < 1), and compound heterozygous mutations in *ALDH7A1* (c.750G>A, p.V250V/c.1195G>C, p.E399Q).¹¹ Dietary lysine restriction and oral arginine supplementation as adjunct to pyridoxine and folinic acid, began at three and eight years, resulted in decreased CSF α -AASA and significant improvements in behaviors and language skills.^{7,8}

Patient #4: insomnia and continuous choreoathetotic movements mimicking neonatal drug withdrawal

This boy was born at 38 weeks (Apgar scores 6 and 8; cord blood pH = 7.09), developed tachypnea, motor hyperexcitability, choreoathetotic movements, and oral stereotypies within the first hours of life. He was hyperalert and manifested insomnia for the first 48 hours of life. Based on a preliminary diagnosis of neonatal substance withdrawal syndrome, he received morphine, which was ineffective. Lactic acidosis (pH 7.11; BE = -17 mmol/L; lactate = 10.8 mmol/L) and subsequent pyridoxine-responsive status epilepticus prompted the diagnosis of ATQ deficiency, which was demonstrated by elevated plasma pipercolic acid (52.3 $\mu\text{mol/L}$, reference range < 2.5) and a homozygous mutation in *ALDH7A1* (c.1195G>C; p.E399Q).

Numerous breakthrough seizures occurred on oral pyridoxine (30 to 35 mg/kg/day). Dietary lysine restriction was initiated at age 40 months. At six years of age, he has a squint, poor oral motor coordination with drooling, and attention deficit disorder.

Patient #5: early-onset myoclonia and delayed response to pyridoxine

This boy was born at 39 weeks with normal Apgar scores. He developed myoclonia during the first two days of life but had no evidence of epileptic activity on EEG. Cranial computed tomography and MRI revealed a small hemorrhage in the left and right occipital and temporal regions. From day 11 onwards, on treatment with phenobarbital, he demonstrated hypertonia of the lower extremities, sunset phenomenon of the eye, hyperalertness, insomnia, poor oral intake, and burst suppression EEG and was unresponsive to 100-mg pyridoxine intravenously. The myoclonia resolved, and his EEG improved on oral topiramate, folinic acid (5 mg/day), and pyridoxine (15 mg/kg/day). Insomnia, jitteriness, and myoclonus recurred one week after discontinuation of pyridoxine and folinic acid. No improvement was observed after

reinstitution of folinic acid, but a single, oral dose of pyridoxine 50 mg was followed by a marked decrease in tone, decrease in startle, and absence of myoclonus. ATQ deficiency was confirmed by elevated plasma pipercolic acid levels (14.4 $\mu\text{mol/L}$, reference = 0.1 to 3.9) and compound heterozygous mutations in *ALDH7A1* (c.248G>A/c.1208C>T; p.G83E/p.P403L). At six months, he exhibited mild motor delay and hypotonia.¹⁴

Patient #6: infantile epileptic encephalopathy responsive to pharmacologic monotherapy and cerebral folate deficiency

This girl developed seizures at age five days of age which were initially responsive to conventional pharmacotherapy. At 12 months of age, she experienced status epilepticus. Seizure control was achieved with levetiracetam. At the age of 11 years, she had intellectual disability and expressive language delay. Her MRI showed left mesial temporal sclerosis, mild periventricular leukomalacia, and bilateral cerebellar volume loss.⁸

Her younger sister, who had a similar presentation of neonatal seizures, was diagnosed with ATQ deficiency (p.G274E/p.S317L) through an epilepsy gene panel⁸ (Patient 2) at age 9 months. Elevated plasma α -AASA confirmed the same diagnosis in this patient. Treatment with pyridoxine 100 mg by mouth three times per day (10 mg/kg/day) was initiated. She was not compliant on lysine-restricted diet. CSF studies obtained while on this regimen showed elevated α -AASA levels at 0.42 $\mu\text{mol/L}$ (reference range < 0.1) and reduced 5-methyltetrahydrofolate at 29 nmol/L (reference range = 40 to 210). Notably, neither this CSF sample nor the CSF sample investigated nine years earlier for monoamine neurotransmitter metabolites identified peak(s) X, characteristically associated with ATQ deficiency.¹³ Conversely, 5-methyltetrahydrofolate was normal (61 nmol/L).

Discussion

More than 200 patients with genetically confirmed pyridoxine-dependent epilepsy have been described in the literature since the identification of *ALDH7A1* as a causative gene, although many more patients are diagnosed in clinical practice. Our review highlights pyridoxine-dependent epilepsy/ATQ deficiency as an epileptic encephalopathy with a complex clinical and biochemical presentation. Classical symptoms such as intractable neonatal seizures responsive to pyridoxine are well known to neonatologists and neurologists, whereas numerous neuroradiologic, systemic, and biochemical features might provide rise to different differential diagnoses and thus delay the final diagnosis. Mills et al.¹¹ provide comprehensive data on symptom frequency in patients diagnosed in their institution. Our goal was to provide an overview of the type of symptoms so as to depict the phenotypic spectrum of this rare condition. We were unable to provide reliable information on the true frequency of the various symptoms, reasons for which include the following (1) reporting bias (i.e., not all those diagnosed are reported, often only patients with rare or unusual phenotypes); (2) incomplete data on patient phenotypes in the literature (i.e., not all cases are comprehensively described and some symptoms might not have been reported); and (3) diagnostic bias (i.e., we only screen for this condition in patients with the classic presentation and thus

miss the diagnosis in atypical presentations). The latter may change now that epilepsy gene panels and genome-wide sequencing are frequently ordered in the clinical setting.

Neonatal onset of seizures unresponsive to pharmacologic treatment is the most common denominator for pyridoxine-dependent epilepsy/ATQ deficiency. More specific associations include myoclonia, hyperalertness, sleeplessness, poor feeding, and vomiting. As illustrated by Patient 4, symptoms can mimic substance withdrawal. Because PLP acts as a cofactor for more than 140 enzymatic reactions,⁵⁶ its reduced availability explains the numerous metabolic derangements, associated with pyridoxine-dependent epilepsy/ATQ deficiency. Aside from hypoglycemia and lactic acidosis, electrolyte disturbances, coagulopathy, abnormal plasma, and CSF amino acid concentrations have been observed, which clearly assigns pyridoxine-dependent epilepsy/ATQ deficiency to the group of metabolic epileptic encephalopathies.

Seizure types vary as illustrated in Fig 2, and onset beyond the neonatal period is uncommon although does occur exemplified by Patient 3. No literature reports were identified describing patients who developed seizures for the first time at age 12 months or older. Such atypical forms may well have been missed due to testing bias; with the advent of genome-wide sequencing, late-onset patients of ATQ deficiency might well be diagnosed in the future.

ATQ deficiency presents with a variety of neurologic symptoms and neuroimaging abnormalities varying from neonatal intracerebral hemorrhage, congenital hydrocephalus and subependymal cysts, to ventriculomegaly, hydrocephalus, and hypoplasia of the corpus callosum.^{12,15–17} In some patients, cerebral heterotopia and cortical malformation may explain the intractable nature of the epilepsy.^{11,18} As demonstrated in Patient 2, loss of white matter after an initial insult in the neonatal period may be progressive, to a degree that exceeds the usual evolution of periventricular malacia observed in prematurity/perinatal asphyxia. Behavioral abnormalities become apparent during early childhood only but were included in Fig 1 because these were prominent in patients who were diagnosed later in life, i.e., missed on initial presentation with the classical early-onset seizures.

Furthermore, as exemplified by Patient #1,¹² the diagnosis of ATQ deficiency can be challenged by the many other biochemical/metabolic abnormalities that can be present during the acute phase.

Response to folinic acid and identification of a characteristic yet unidentified metabolite (Peak X) in the CSF, previously led to the assumption that folinic acid-responsive seizures are a separate clinical entity.¹³ Only recently has it been shown that folinic acid-responsive seizures and ATQ deficiency are allelic.¹⁴ The results of Patient #6 indicate that the peak(s) observed on monoamine neurotransmitter analysis are not fully sensitive for ATQ deficiency and that α -AASA in blood, urine, or CSF and/or molecular analysis are essential. The identification of low 5-methyltetrahydrofolate in CSF suggests that this might be assessed in patients with pyridoxine-dependent epilepsy, and supplementation with folinic acid could be considered if the value is low, although clear evidence of benefit for this patient population is currently lacking.

As illustrated by Patient #5 and 14% of patients reported by Mills et al.,¹¹ not all children respond immediately to

pyridoxine. Thus clinical diagnosis should be focused on biochemical metabolites and not solely on response to pyridoxine, which has incomplete sensitivity and specificity.

In spite of effective treatment of seizures with pyridoxine, approximately 70% of affected individuals with pyridoxine-dependent epilepsy suffer developmental delay/intellectual disability. New treatments targeting the metabolic defect in lysine degradation,^{7,8} potentially improve long-term developmental and cognitive outcomes, and the preliminary data are promising. This review of clinical manifestations may help the clinician to identify patients at risk, particularly if they present with atypical/rare manifestations. Collaborative, observational studies are underway with the PDE Patient Registry (www.pdeonline.org), an active data collection study, to better understand the clinical spectrum and long-term outcomes associated with the various available treatment modalities.

Overall, pyridoxine-dependent epilepsy due to ATQ deficiency is a treatable cause of epilepsy and intellectual disability.⁵⁷ Diagnosis of ATQ deficiency is established by determination of α -AASA/P6C in blood or urine (see <https://www.genetests.org/> for an overview of clinical laboratories providing this test). Elevation of α -AASA/P6C persists on treatment with pyridoxine. Thus patients at risk should immediately be treated with pyridoxine orally or intravenously, and diagnostic urine and blood samples can be taken any time after initiation of treatment.¹ Picoelic acid is another diagnostic marker.⁵⁸ However, although analysis of this marker is widely available, its specificity for the diagnosis of ATQ deficiency is limited. Molecular analysis of the ATQ gene (*ALDH7A1*) is performed for diagnostic confirmation. If sequencing does not reveal point mutations, molecular testing for insertions, copy number variants, and intronic variants should be performed.⁵⁹ To date, more than 80 mutations have been reported within the 18 exons of *ALDH7A1* on the Human Gene Mutation Database web site. The missense mutation, p.E399Q in exon 14, occurs in various populations and accounts for about 30% of published alleles.^{11,23,60} If biochemical/molecular analyses are negative, then other genetic causes of pyridoxine-responsive seizures should be considered, including (but not limited to) pyridoxamine 5'-phosphate oxidase deficiency (MIM# 610090)⁶¹ and hypophosphatasia due to alkaline phosphatase deficiency (MIM #241500).⁶²

The wide range of clinical presentations of pyridoxine-dependent epilepsy that hamper diagnostic recognition of this treatable neurometabolic disorder supports further development of a reliable and affordable method of newborn screening (e.g., via determination of α -AASA/P6C in blood spots⁶³), followed by a pilot study to enable timely identification and immediate initiation of treatment to optimize patient outcomes. We propose that all infants presenting with unexplained seizures should be screened for ATQ deficiency by determination of α -AASA/P6C in urine/plasma and, if abnormal, subsequent *ALDH7A1* molecular analysis (or *vice versa*). A vitamin B6 trial should be provided at a low threshold. Given its amenability to adjunct nutritional therapy and the potential positive impact on seizure control and development, even, when initiated at an older age, this rare metabolic epilepsy could be considered in the older children with intractable seizures as well.

The authors are grateful for the patients and families allowing us to describe their clinical case reports. The authors acknowledge the following individuals for providing biochemical and genetic data described here: (1) Dr. B. Plecko, MD, PhD (Department of Pediatrics Medical University of Graz, Austria) performed *ALDH7A1* mutation analysis and analysis of plasma pipercolic acid in Patients #1, 3, and 4; (2) Dr. E. Struys, PhD and Dr. C. Jakobs, PhD (Free University Medical Centre, Amsterdam, the Netherlands) performed urine α -AASA analysis in Patients #2, 3, and 5; (3) Dr. G. Salomons, PhD (Free University Medical Centre, Amsterdam, the Netherlands) performed mutation analysis in Patients #2 and 5; (4) Dr. R. Jack, PhD (Seattle Children's Hospital, Washington University, United States of America) performed α -AASA analysis in Patient #6; (5) Dr. G. Scharer, MD PhD (Denver Children's Hospital, University of Colorado, United States of America) performed mutation analysis in Patients #5 and 6; and (6) Dr. K. Hyland, PhD (Medical Neurogenetics, Atlanta, United States of America) performed CSF monoamine neurotransmitter analysis in Patient #6. The authors are grateful to Ms. C. Sowerbutt for editing the article. This study was supported by funding support provided by the BC Children's Hospital Foundation, Vancouver Canada as the 1st Collaborative Area of Innovation (TIDE-BC, www.tidebc.org). CvK is a recipient of the Michael Smith Foundation for Health Research Scholar Award. The PDE research of CC is supported by the PDE Foundation.

References

- Stockler S, Plecko B, Gospe Jr SM, et al. Pyridoxine dependent epilepsy and antiquitin deficiency: clinical and molecular characteristics and recommendations for diagnosis, treatment and follow-up. *Mol Genet Metab*. 2011;104:48–60.
- Gospe SM. Pyridoxine-dependent epilepsy. *Gene-reviews*; 2012. Bookshelf ID: NBK1486 PMID: 20301659.
- Baxter P. Epidemiology of pyridoxine dependent and pyridoxine responsive seizures in the UK. *Arch Dis Child*. 1999;81:431–433.
- Ebinger M, Schultze C, König S. Demographics and diagnosis of pyridoxine-dependent seizures. *J Pediatr*. 1999;134:795–796.
- Bok LA, Halbertsma FJ, Houterman S, et al. Long-term outcome in pyridoxine-dependent epilepsy. *Dev Med Child Neurol*. 2012;54:849–854.
- Mills PB, Struys E, Jakobs C, et al. Mutations in antiquitin in individuals with pyridoxine-dependent seizures. *Nat Med*. 2006;12:307–309.
- van Karnebeek CD, Hartmann H, Jaggumantri S, et al. Lysine restricted diet for pyridoxine-dependent epilepsy: first evidence and future trials. *Mol Genet Metab*. 2012;107:335–344.
- Coughlin 2nd CR, van Karnebeek CD, Al-Hertani W, et al. Triple therapy with pyridoxine, arginine supplementation and dietary lysine restriction in pyridoxine-dependent epilepsy: neurodevelopmental outcome. *Mol Genet Metab*. 2015;116:35–43.
- van Karnebeek CD, Stockler-Ipsiroglu S, Jaggumantri S, et al. Lysine-restricted diet as adjunct therapy for pyridoxine-dependent epilepsy: the PDE consortium consensus recommendations. *JIMD Rep*. 2014;15:1–11.
- van Karnebeek CD, Jaggumantri S. Current treatment and management of pyridoxine-dependent epilepsy. *Curr Treat Options Neurol*. 2015;17:335.
- Mills PB, Footitt EJ, Mills KA, et al. Genotypic and phenotypic spectrum of pyridoxine-dependent epilepsy (ALDH7A1 deficiency). *Brain*. 2010;133:2148–2159.
- Mercimek-Mahmutoglu S, Horvath GA, Coulter-Mackie M, et al. Profound neonatal hypoglycemia and lactic acidosis caused by pyridoxine-dependent epilepsy. *Pediatrics*. 2012;129:e1368–e1372.
- Hyland K, Buist NRM, Powell BR, et al. Folinic acid responsive seizures: a new syndrome? *J Inherit Metab Dis*. 1995;18:177–181.
- Gallagher RC, Van Hove JL, Scharer G, et al. Folinic acid-responsive seizures are identical to pyridoxine-dependent epilepsy. *Ann Neurol*. 2009;65:550–556.
- Jain-Ghai S, Mishra N, Hahn C, Blaser S, Mercimek-Mahmutoglu S. Fetal onset ventriculomegaly and subependymal cysts in a pyridoxine dependent epilepsy patient. *Pediatrics*. 2014;133:e1092–e1096.
- Friedman SD, Ishak GE, Poliachik SL, et al. Callosal alterations in pyridoxine-dependent epilepsy. *Dev Med Child Neurol*. 2014;56:1106–1110.
- Ishak GE, Friedman SD, Poliakov AV, Poliachik SL, Shaw DWW, Gospe SM. Callosal and white matter features in pyridoxine-dependent epilepsy (PDE). *J Inherit Metab Dis*. 2012;35:S136.
- Jansen LA, Hevner RF, Roden WH, Hahn SH, Jung S, Gospe Jr SM. Glial localization of antiquitin: implications for pyridoxine-dependent epilepsy. *Ann Neurol*. 2014;75:22–32.
- Plecko B, Hikel C, Korenke GC, et al. Biochemical and molecular characterization of 18 patients with pyridoxine-dependent epilepsy and mutations of the antiquitin (*ALDH7A1*) gene. *Hum Mutat*. 2007;28:19–26.
- Alfadhel M, Sirrs S, Waters PJ, et al. Variability of phenotype in two sisters with pyridoxine dependent epilepsy. *Can J Neurol Sci*. 2012;39:516–519.
- Al-Saman AS, Rizk TM. A case of extreme prematurity and delayed diagnosis of pyridoxine-dependent epilepsy. *Neurosciences (Riyadh, Saudi Arabia)*. 2012;17:371–373.
- Basura GJ, Hagland SP, Wiltse AM, Gospe Jr SM. Clinical features and the management of pyridoxine-dependent and pyridoxine-responsive seizures: review of 63 North American cases submitted to a patient registry. *Eur J Pediatr*. 2009;168:697–704.
- Bennett CL, Chen Y, Hahn S, Glass IA, Gospe Jr SM. Prevalence of *ALDH7A1* mutations in 18 North American pyridoxine-dependent seizure (PDS) patients. *Epilepsia*. 2009;50:1167–1175.
- Dogan DG, Kahraman AS, Ozcan O, Yakinci C, Alkan A. A 9-year follow-up of a girl with pyridoxine (vitamin B6)-dependent seizures: magnetic resonance spectroscopy findings. *Eur Rev Med Pharmacol Sci*. 2012;16:695–698.
- Jagadeesh S, Suresh B, Murugan V, et al. Pyridoxine-dependent epilepsy owing to antiquitin deficiency—mutation in the *ALDH7A1* gene. *Paediatrics Int Child Health*. 2013;333:113–115.
- Kabakus N, Aydin M, Ugur SA, Durukan M, Tolun A. Very-late-onset pyridoxine-dependent seizures not linking to the known *Sq31* locus. *Pediatr Int*. 2008;50:703–705.
- Kaczorowska M, Kmiec T, Jakobs C, et al. Pyridoxine-dependent seizures caused by alpha amino adipic semialdehyde dehydrogenase deficiency: the first polish case with confirmed biochemical and molecular pathology. *J Child Neurol*. 2008;23:1455–1459.
- Kluger G, Blank R, Paul K, et al. Pyridoxine-dependent epilepsy: normal outcome in a patient with late diagnosis after prolonged status epilepticus causing cortical blindness. *Neuropediatrics*. 2008;39:276–279.
- Kumar P, Gupta VK, Mishra D. Non-compliance in pyridoxine-dependent seizures and a way out. *J Paediatr Child Health*. 2007;43:571–572.
- Koul R. Pyridoxine-dependent seizures: 10-year follow-up of eight cases. *Neurol India*. 2009;57:460–463.
- Lin J, Lin K, Masruha MR, Vilanova LC. Pyridoxine-dependent epilepsy initially responsive to phenobarbital. *Arquivos de Neuro-Psiquiatria*. 2007;65:1026–1029.
- Mercimek-Mahmutoglu S, Donner EJ, Siriwardena K. Normal plasma pipercolic acid level in pyridoxine dependent epilepsy due to *ALDH7A1* mutations. *Mol Genet Metab*. 2013;110:197.
- Milh M, Pop A, Kanhai W, et al. Atypical pyridoxine-dependent epilepsy due to a pseudoxon in *ALDH7A1*. *Mol Genet Metab*. 2012;105:684–686.
- Millet A, Salomons GS, Cneude F, et al. Novel mutations in pyridoxine-dependent epilepsy. *Eur J Paediatr Child Health*. 2011;15:74–77.
- Naasan G, Yabroudi M, Rahi A, Mikati MA. Electroencephalographic changes in pyridoxine-dependant epilepsy: new observations. *Epileptic Disord*. 2009;11:293–300.
- Nasr E, Mamak E, Feigenbaum A, Donner EJ, Mercimek-Mahmutoglu S. Long-term treatment outcome of two patients with pyridoxine-dependent epilepsy caused by *ALDH7A1* mutations: normal neurocognitive outcome. *J Child Neurol*. 2014;30:648–653.
- Niermeijer JMF, Abeling N, Koelman HJ, Poll-The BT. Pyridoxine dependent epilepsy: clinical features and progressive serial brain MRI abnormalities. *J Inherit Metab Dis*. 2012;35:S136.
- Oliveira R, Pereira C, Rodrigues F, et al. Pyridoxine-dependent epilepsy due to antiquitin deficiency: achieving a favourable outcome. *Epileptic Disord*. 2013;15:400–406.
- Pérez B, Gutiérrez-Solana LG, Verdú A, et al. Clinical, biochemical, and molecular studies in pyridoxine-dependent epilepsy. Antisense therapy as possible new therapeutic option. *Epilepsia*. 2013;54:239–248.
- Proudfoot M, Jardine P, Straukiene A, et al. Long-term follow-up of a successfully treated case of congenital pyridoxine-dependent epilepsy. *JIMD Rep*. 2013;10:103.

41. Rankin PM, Harrison S, Chong WK, Boyd S, Aylett SE. Pyridoxine-dependent seizures: a family phenotype that leads to severe cognitive deficits, regardless of treatment regime. *Dev Med Child Neurol.* 2007;49:300–305.
42. Russell KE, Mulligan SR, Mallory LA. Diagnosis of pyridoxine-dependent seizures in a nineteen-year-old patient. *Pediatr Neurol.* 2012;47:141.
43. Scharer G, Brocker C, Vasiliou V, et al. The genotypic and phenotypic spectrum of pyridoxine-dependent epilepsy due to mutations in ALDH7A1. *J Inherit Metab Dis.* 2010;33:571–581.
44. Schmitt B, Baumgartner M, Mills PB, et al. Seizures and paroxysmal events: symptoms pointing to the diagnosis of pyridoxine-dependent epilepsy and pyridoxine phosphate oxidase deficiency. *Dev Med Child Neurol.* 2010;52:e133–e142.
45. Segal EB, Grinspan ZM, Mandel AM, Gospe Jr SM. Biomarkers aiding diagnosis of atypical presentation of pyridoxine-dependent epilepsy. *Pediatr Neurol.* 2011;44:289–291.
46. Striano P, Battaglia S, Giordano L, et al. Two novel ALDH7A1 (anti-quitin) splicing mutations associated with pyridoxine-dependent seizures. *Epilepsia.* 2009;50:933–936.
47. Tamaura M, Shimbo H, Iai M, Yamashita S, Osaka H. Seizure recurrence following pyridoxine withdrawal in a patient with pyridoxine-dependent epilepsy. *Brain Dev.* 2014;37:442–445.
48. Tlili A, Hamida Hentati N, Chaabane R, Gargouri A, Fakhfakh F. Pyridoxine-dependent epilepsy in Tunisia is caused by a founder missense mutation of the ALDH7A1 gene. *Gene.* 2013;518:242–245.
49. Tincheva S, Todorov T, Todorova A, et al. First cases of pyridoxine-dependent epilepsy in Bulgaria: novel mutation in the ALDH7A1 gene. *Neurol Sci.* 2015;36:2209–2212.
50. van Karnebeek CD, Hartmann H, Jaggamantri S, et al. Lysine restricted diet for pyridoxine-dependent epilepsy: first evidence and future trials. *Mol Genet Metab.* 2012;12:344–347.
51. Ville D, Ginguene C, Marignier S, des Portes V, de Bellescize J. Early diagnosis of pyridoxine-dependent epilepsy: video-EEG monitoring and biochemical and genetic investigation. *Eur J Paediatr Neurol.* 2013;17:676–680.
52. Yang Z, Yang X, Wu Y, et al. Clinical diagnosis, treatment, and ALDH7A1 mutations in pyridoxine-dependent epilepsy in three Chinese infants. *PLoS One.* 2014;9:e92803.
53. Yeghiazaryan NS, Striano P, Spaccini L, et al. Long-term follow-up in two siblings with pyridoxine-dependent seizures associated with a novel ALDH7A1 mutation. *Eur J Paediatr Neurol.* 2011;15:547–550.
54. Yeghiazaryan NS, Zara F, Capovilla G, Brigati G, Falsaperla R, Striano P. Pyridoxine-dependent epilepsy: an under-recognised cause of intractable seizures. *J Paediatr Child Health.* 2012;48:e113–e115.
55. Yusuf IH, Sandford V, Hildebrand GD. Congenital cataract in a child with pyridoxine-dependent epilepsy. *J AAPOS.* 2013;17:315–317.
56. Stöckler-Ipsiroglu S, van Karnebeek CDM. (Pyridoxine and pyridoxal-phosphate dependent epilepsies). In: Hoffmann GF, Blau N, eds. *Congenital Neurotransmitter Disorders.* Nova Science Publishers; 2014:149–166.
57. van Karnebeek CD, Stockler S. Treatable inborn errors of metabolism causing intellectual disability: a systematic literature review. *Mol Genet Metab.* 2012;103:368–381.
58. Plecko B, Hikel C, Korenke GC, et al. Pilocarpic acid as a diagnostic marker of pyridoxine-dependent epilepsy. *Neuropediatrics.* 2005;36:200–205.
59. Mefford HC, Zemel M, Geraghty E, et al. Intragenic deletions of ALDH7A1 in pyridoxine-dependent epilepsy caused by Alu-Alu recombination. *Neurology.* 2015;85:756–762.
60. Kanno J, Kure S, Narisawa A, et al. Allelic and non-allelic heterogeneities in pyridoxine dependent seizures revealed by ALDH7A1 mutational analysis. *Mol Genet Metab.* 2007;91:384–389.
61. Plecko B, Paul K, Mills P, et al. Pyridoxine-responsiveness in novel mutations of the PNPO gene. *Neurology.* 2014;82:1425–1433.
62. de Roo MG, Abeling NG, Majoie CB, et al. Infantile hypophosphatasia without bone deformities presenting with severe pyridoxine-resistant seizures. *Mol Genet Metab.* 2014;111:404–407.
63. Jung S, Tran NT, Gospe Jr SM, Hahn SH. Preliminary investigation of the use of newborn dried blood spots for screening pyridoxine-dependent epilepsy by LC-MS/MS. *Mol Genet Metab.* 2013;110:237–240.